


Novel Approach using TransOral Robotic Surgery for Resection of Cervical Spine Chordoma



Ahmad F. Mahmoud, MD¹; Adam McCann, BS²; Neil R. Malhotra, MD¹; Bert W. O'Malley, Jr., MD¹
¹University of Pennsylvania, ²Kansas University Medical Center

Introduction

Chordomas are rare infiltrative tumors that arise from remnants of the notochord. They are predominantly located in the sacrum and clivus, however, 6% are located in the cervical spine.¹ Surgery is the mainstay of therapy and the extent of tumor removal is a significant prognostic factor in these patients. Therefore, en bloc resection is the goal in these cases.^{2,3} This is often limited in the head and neck region due to difficulty with visualization, access, and proximity of surrounding critical structures.

Tumor location is a critical factor when considering a surgical approach. Multiple operative techniques for anterior visualization of cervical chordomas have been reported. Among these, transoral approaches offer superior midline visualization, however, they often introduce significant comorbidity due to the need to increase access through additional procedures such as glossotomy, mandibulotomy, maxillotomy, or palatotomy.^{4,5} TransOral Robotic Surgery (TORS) has been utilized for over a decade to provide access to tumors in the oropharynx. This approach offers shared visualization, angled scopes, binocular vision coupled with articulating instrumentation, and tremor dampening.⁶⁻⁸ Additionally, TORS has allowed head and neck surgeons to avoid the need for the aforementioned procedures for accessing the oropharynx, thereby avoid significant comorbidity. Here, we present the first documented case of TORS for access to chordoma of the cervical spine.

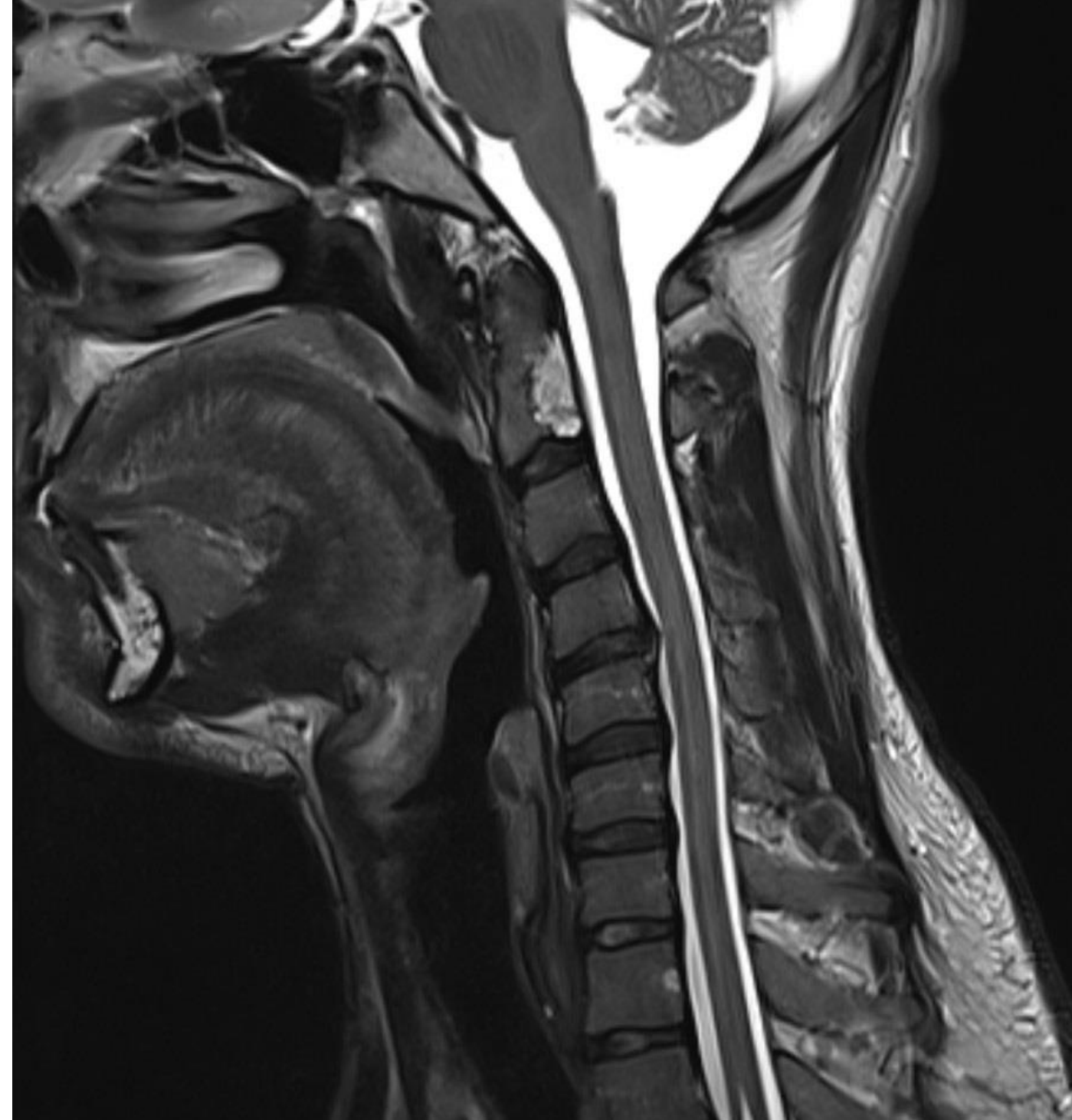

Figure 2. Sagittal MRI (T2) showing chordoma on posterior aspect of C2 vertebral body.

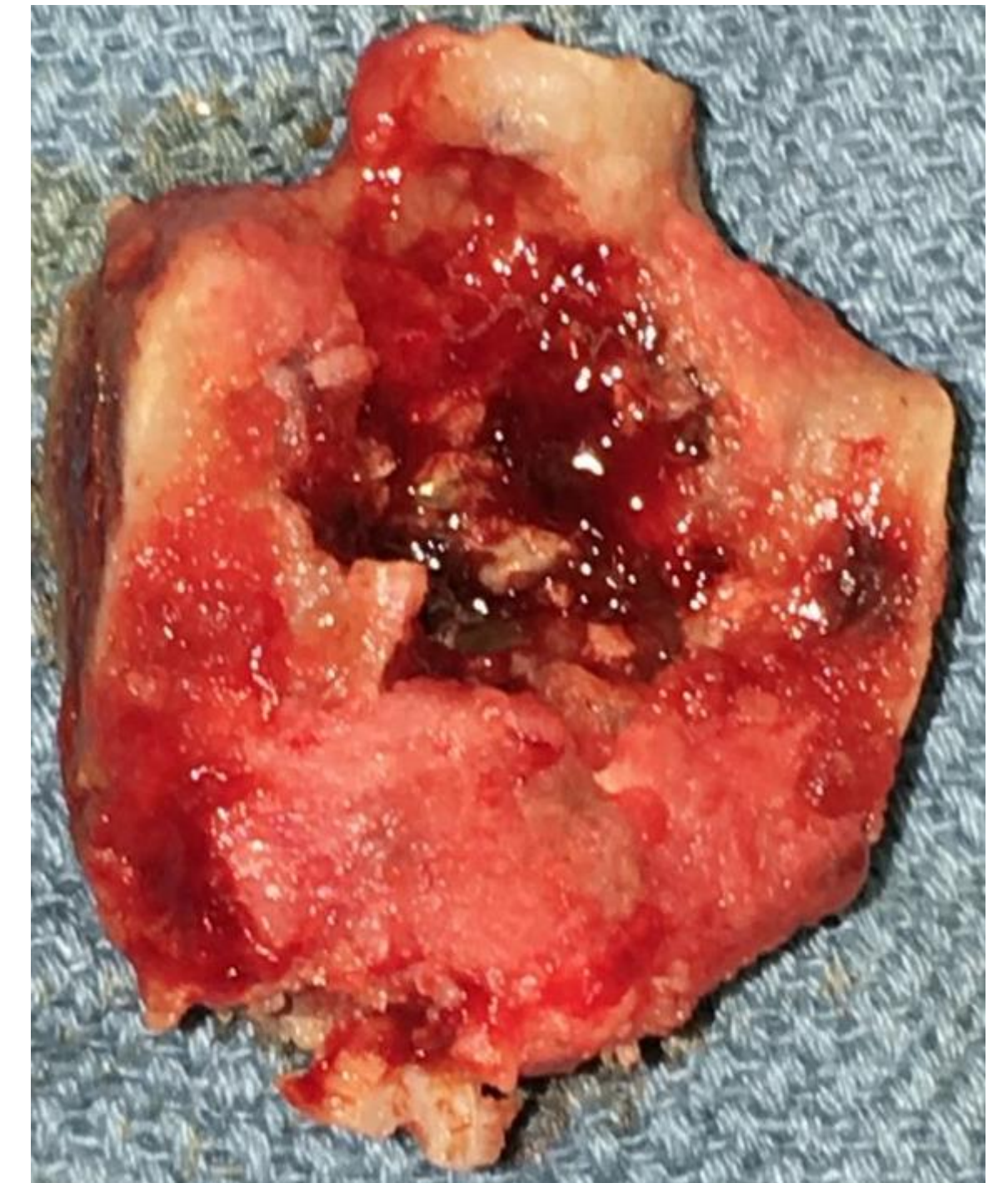

Figure 3. C2 vertebral body with lesion visible on posterior aspect.

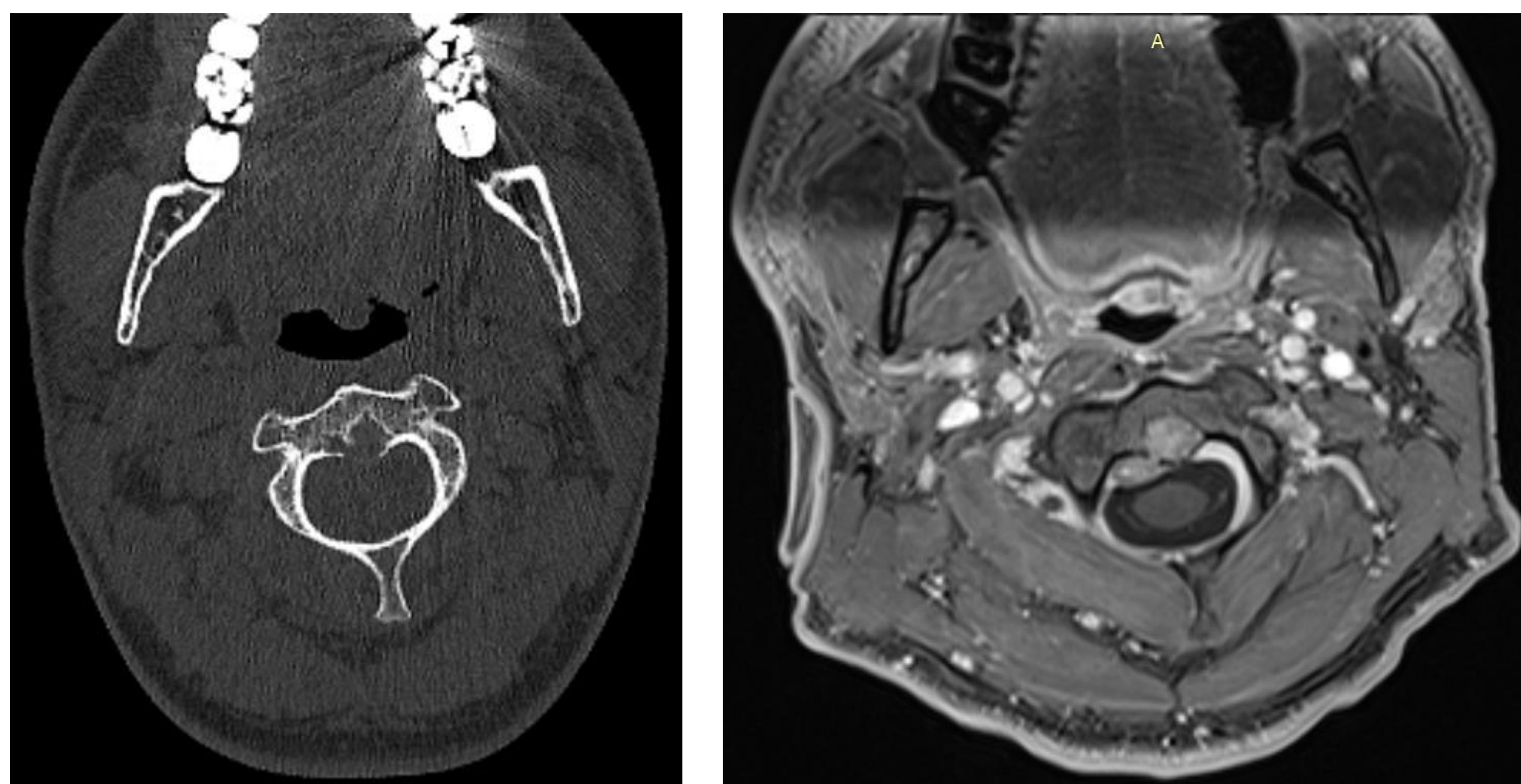


Figure 1. Axial CT and MRI (T1, post-contrast). Lesion can be seen on the posterior aspect of the C2 vertebral body.

Case Report

The patient is a 27-year-old healthy male with an incidentally diagnosed mass in the cervical spine following a motor vehicle collision. Subsequent workup revealed this to be a 2.2 cm chordoma centered in midline on the posterior aspect of the C2 vertebral body. Due to location, the patient was initially recommended for radiation therapy. Upon presenting to our institution for a second opinion, surgical resection was recommended using TORS with the goal of en bloc resection and avoidance of radiation therapy.

The patient was taken to the operating room for a staged procedure. The first procedure included a posterior approach with C1, C2, and C3 laminectomies followed by linear osteotomies of the vertebral bodies from posterior to anterior at levels C1 through C3 and partial posterior discectomies at levels C2 and C3.

The following day, the patient was brought to operating room for second stage which involved anterior approach with TORS. Using standard TORS approach for the oropharynx a midline vertical incision was made from nasopharynx down to the level of the tongue base using image guidance. This was carried down to the subperiosteal plane and dissection carried out laterally in order to expose vertebral bodies C2 through C4 as well as the lateral linear osteotomies bilaterally. The C2 vertebral body was resected en bloc. An iliac crest graft was plated in its place. Posteriorly, arthrodesis was performed from occiput to C6. A tracheostomy was performed and nasogastric feeding tube placed.

Postoperative course was complicated by dehiscence and infection of anterior hardware which was treated conservatively with long-term intravenous antibiotics and temporary gastrostomy tube to avoid oral intake. The patient had full recovery including tracheostomy decannulation, gastrostomy removal, and completion of antibiotic course within three months. At 6 months post-surgery he shows no sign of recurrence, has no long-term sequela from surgery and has avoided radiation.

Discussion

Multiple factors should be considered in planning surgical resection of a chordoma such as size, location, and proximity of surrounding structures. With regards to the cervical spine, the approach often dictates the extent of resection possible. The transcervical approach is often utilized for subaxial or lateral lesions but is not reliable for midline lesions due to the inability to access the contralateral margin.^{5,9,10} In an attempt to obtain en bloc resection with negative margins, it is critical to avoid violating the tumor as this has been shown to increase recurrence and seed the surgical site.¹¹ Transoral approaches provide excellent midline visualization but without TORS, access would be achieved at a significant cost of comorbidity. Finally, radiation alone is an option but not ideal given suboptimal treatment response and long-term side effects, especially given this patient's young age.

As the first of its kind, there will always be lessons to be learned. To prevent dehiscence, one may consider prolonging the NPO status in order to allow for better healing, alternatively a rotational pharyngeal muscle flap could be considered to bolster initial closure of the posterior pharynx. Instead, we opted for a multilayer advancement closure of the posterior constrictors and longus coli muscles in order to minimize dysphagia and aspiration risk. Upon recognizing the dehiscence, a discussion of rotational flap or free flap to posterior pharynx was considered along with hardware removal. However, we chose to pursue long-term antibiotics and secondary wound healing due to neurosurgical experience and literature which supports this option over hardware removal for exposed or infected cervical hardware.^{12,13}

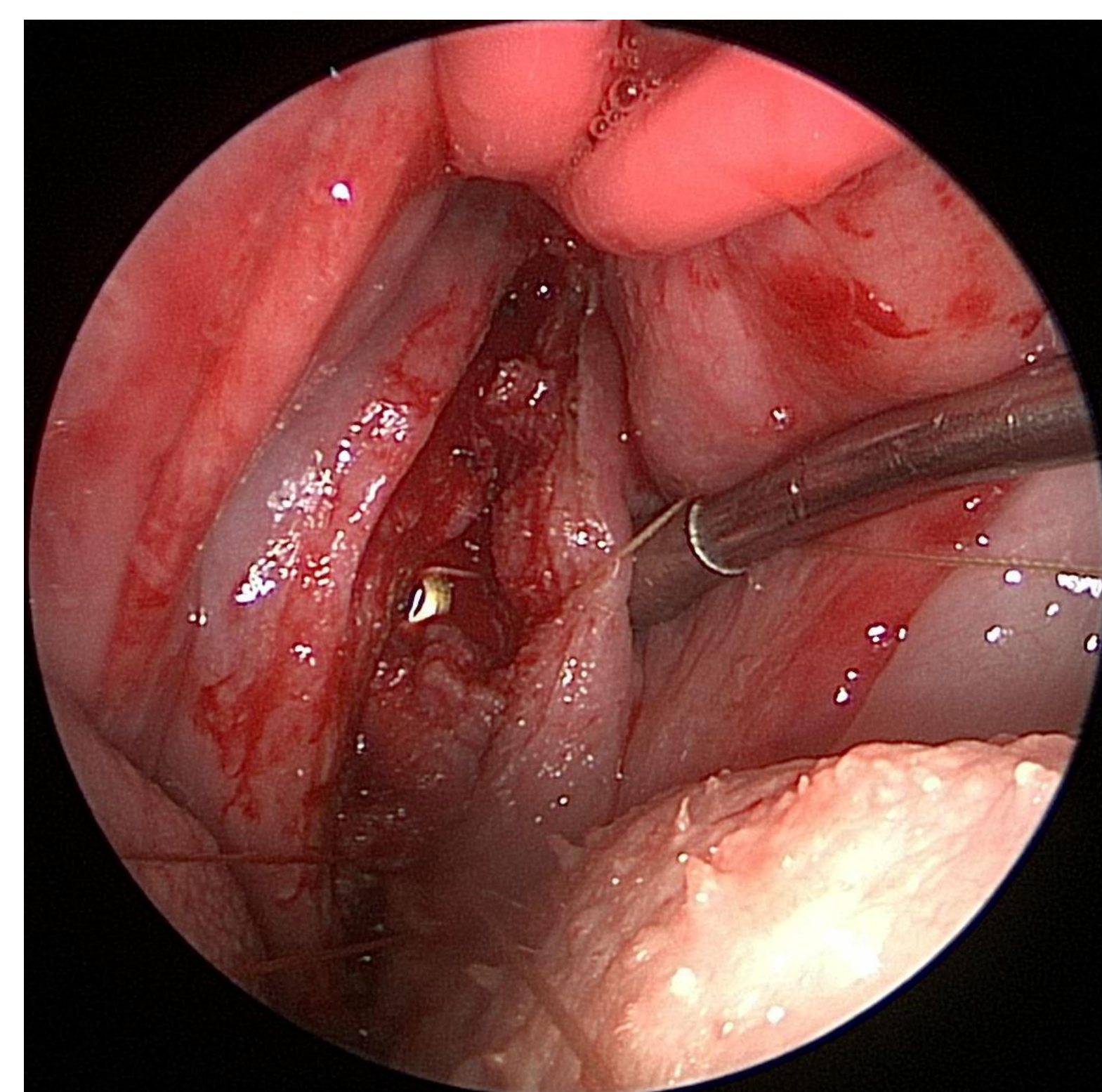


Figure 4. Transoral view of posterior pharynx following resection of tumor, cervical plate is seen within the incision. Palate is retracted superiorly and anteriorly with bilateral red-rubber catheters.

Conclusions

Uncompromised access with acceptable comorbidity is the goal in any surgery and was felt to be feasible in this case with the use of TORS. We obtained a complete resection of the tumor and although this patient's postoperative course was prolonged, he made a complete recovery with minimal long-term side effects.

Contact

Ahmad F. Mahmoud, MD
University of Pennsylvania
Email: ahmad.mahmoud@uphs.upenn.edu

References

- Boriani S, Bandiera S, Biagini R, et al. Chordoma of the mobile spine: fifty years of experience. *Spine*. 2006;31(4):493-503.
- Logroscino CA, Astolfi S, Sacchetti G. Chordoma: long-term evaluation of 15 cases treated surgically. *Chir Organi Mov*. 1998;83(1-2):87-103.
- Bergh P, Kindblom LG, Gunterberg B, Remotti F, Ryd W, Meis-Kindblom JM. Prognostic factors in chordoma of the sacrum and mobile spine: a study of 39 patients. *Cancer*. 2000;88(9):2122-2134.
- Weil AG, Shehadeh M, Ayad T, Abboud O, Shedid D. En bloc resection of a C2-C3 upper cervical chordoma: Technical note. *Surg Neurol Int*. 2015;6(Suppl 24):S615-S618.
- Ito K, Nakamura T, Aoyama T, Horiuchi T, Hongo K. A Case of Laterally Extended High-Positioned Chordoma Treated Using the High Cervical Retropharyngeal Approach. *World Neurosurg*. 2017;105:1043.e15-1043.e19.
- Hockstein NG, O'Malley BW, Weinstein GS. Assessment of intraoperative safety in transoral robotic surgery. *The Laryngoscope*. 2006;116(2):165-168.
- O'Malley BW, Weinstein GS, Snyder W, Hockstein NG. Transoral robotic surgery (TORS) for base of tongue neoplasms. *The Laryngoscope*. 2006;116(8):1465-1472.
- Weinstein GS, O'Malley BW, Snyder W, Hockstein NG. Transoral robotic surgery: supraglottic partial laryngectomy. *Ann Otol Rhinol Laryngol*. 2007;116(1):19-23.
- Vassal F, Dumas B, Nuti C. Margin-free, en bloc resection of a multilevel cervical chordoma with C-2 involvement: case report with 2-year follow-up and description of operative technique. *Br J Neurosurg*. 2012;26(6):929-931.
- Molina CA, Ames CP, Chou D, et al. Outcomes following attempted en bloc resection of cervical chordomas in the C-1 and C-2 region versus the subaxial region: a multi-institutional experience. *J Neurosurg Spine*. 2014;21(3):348-356.
- Arnaudović KI, Al-Mefty O. Surgical seeding of chordomas. *J Neurosurg*. 2001;95(5):798-803.
- Kasliwal MK, Tan LA, Traynelis VC. Infection with spinal instrumentation: Review of pathogenesis, diagnosis, prevention, and management. *Surg Neurol Int*. 2013;4(Suppl 5):S392-S403.
- Dobran M, Marini A, Gladi M, et al. Deep spinal infection in instrumented spinal surgery: diagnostic factors and therapy. *Il G Chir*. 2017;38(3):124-129.